

Art of using maintenance therapy in a patient with metastatic colon cancer harboring *RAS-wt/BRAF V600E*

Mehrdad Payandeh¹, Afshin Karami², Noorodin Karami^{3,*}



Use your smartphone to scan this QR code and download this article

ABSTRACT

Background: Colorectal cancer is one of the most common malignancies with a high rate of liver metastasis, and various gene mutations have been proven to be involved in its pathogenesis. One of them is *BRAF* gene mutations, the most frequent of which—V600E—has a poor prognosis in patients with colon cancer. **Case presentation:** By applying the FOLFIRINOX regimen and a specific maintenance strategy containing vemurafenib, we achieved disappearance of metastatic lesions, no recurrence, and good stability in a Kurdish patient with metastatic colon cancer harboring *RAS-wt/BRAF V600E*. **Conclusion:** Our therapeutic strategy allows the selection of the most appropriate treatment approach for patients.

Key words: Colon cancer, FOLFIRINOX, *BRAF V600E*, Vemurafenib

INTRODUCTION

Colorectal cancer (CRC) is the second leading cause of cancer death and the third most common cancer worldwide¹. Distant metastases occur in approximately 65% of cases. The liver is the most common site of CRC metastasis (20 — 30%), followed by the lungs (10 — 25%)^{2,3}. The survival rate is lower in men than in women, while the 5-year survival rate is poorer for rectal cancer than for colon cancer⁴. Generally, CRC affects 71% of the colon and 29% of the rectum⁵. Sporadic cases are observed in approximately 70% of patients, and environmental and dietary factors are mainly involved. Hereditary predisposition is noted in < 10% of patients and occurs owing to several genetic changes, which can be identified through specific genetic tests^{5,6}.

Based on the different molecular mechanisms involved in CRC, many treatment methods can be used. The most important molecular mechanisms underlying different subtypes of CRC are microsatellite instability, chromosomal instability, and DNA repair machinery error⁷. As a serine/threonine kinase, v-raf murine sarcoma viral oncogene homolog B1 (*BRAF*) is located downstream of the mitogen-activated protein kinase (MAPK)/epidermal growth factor receptor (EGFR) signaling pathway⁸. The V600E mutation of this gene permanently activates the MAPK pathway and is associated with epigenetic activation of MLH1, resulting in the microsatellite instability phenotype in patients with CRC^{9,10}. This mutation occurs in a specific subtype of CRC with a poor prognosis. After

performing molecular and diagnostic tests, we determined that our patient had *RAS-wt/BRAF V600E* mutation; we immediately treated her with the FOLFIRINOX regimen and a specific maintenance therapy and obtained promising results.

CASE PRESENTATION

In February 2019, a 45-year-old Kurdish woman was referred to the Kermanshah Hematology and Oncology Clinic with symptoms of weight loss and abdominal pain. The patient had no relevant clinical history. Following a physical examination of the patient, the physician requested an abdominal CT. Laboratory examination indicated an increase in the CEA and CA19-9 levels and a decrease in the RBC indices. The complete blood count (CBC) testing results were as follows: platelet count: 284 (normal range: 120 – 450) × 10⁹/L, hemoglobin level: 9.1 (normal range: 11.5 – 16.5) g/dL, and white blood cell (WBC) count: 6.6 (normal range: 3.5 – 11) × 10⁹/L. CT illustrated a fungating tumor with a diameter of 40 × 26 mm seen in the transverse colon. Subsequently, PET-CT displayed primary lesions as mural thickening in the splenic flexure of the transverse colon with mesenteric lymph node involvement and multiple metastatic lesions on the right side of the liver. A panel of genetic tests, including tests for *KRAS*, *NRAS*, *PLD1*, and *BRAF* mutations, was performed; only *BRAF* mutation (V600E) tested positive. Based on these findings, the patient was diagnosed with disseminated colon cancer and treated

¹Department of Hematology and Medical Oncology, Kermanshah University of Medical Sciences, Kermanshah, Iran

²Department of Hematology, Shahid Beheshti University of Medical Sciences, Tehran, Iran

³Department of Genetics, Shahid Sadoughi University of Medical Sciences, Yazd, Iran

Correspondence

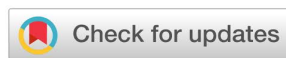Noorodin Karami, Department of Genetics, Shahid Sadoughi University of Medical Sciences, Yazd, Iran

Email: Noorodin.karami@yahoo.com

History

- Received: Jul 31, 2022
- Accepted: Sep 24, 2022
- Published: Sep 30, 2022

DOI : 10.15419/bmrat.v9i9.767



Copyright

© Biomedpress. This is an open-access article distributed under the terms of the Creative Commons Attribution 4.0 International license.



Cite this article : Payandeh M, Karami A, Karami N. Art of using maintenance therapy in a patient with metastatic colon cancer harboring *RAS-wt/BRAF V600E*. *Biomed. Res. Ther.* 2022; 9(9):5301-5305.

with 12 cycles of the FOLFIRINOX regimen (leucovorin, 5-fluorouracil [FU], irinotecan, and oxaliplatin) and cetuximab (Erbix) therapy. The metastatic lesions resolved within 2 weeks after the chemotherapy courses. Thereafter, total colectomy and hyperthermic intraperitoneal chemotherapy were conducted in the transverse colon, and the tumor lesions were removed.

Pathological examination did not show any tumors. Owing to the good response and poor prognosis of *BRAF* mutation in the colon tumor, the patient received a maintenance therapy regimen consisting of capecitabine, vemurafenib, and Erbitux for more than 2 years. During this time, the initial response to maintenance therapy was relatively good, and the CBC testing results were as follows: platelet count: $150 \times 10^9/L$, hemoglobin level: 11.6 g/dL, and WBC count: $5.4 \times 10^9/L$. Similarly, there was no evidence of residual invasive tumor in the colon pathology report. The patient currently receives continual treatment with gradual tapering of these combinations and is followed up regularly.

DISCUSSION

The *BRAF* gene has 18 exons, and its gene locus is on chromosome 7 and functions as a proto-oncogene¹¹. This serine/threonine protein kinase is an important signaling molecule in the EGFR-mediated MAPK pathway, the activation of which is mediated by GTPase/RAS⁸. This pathway and the closely related phosphatidylinositol 3-kinase/AKT signaling pathway play a substantial role in the transcription of genes involved in cancer progression. Therefore, abnormalities involved in the activation of these pathways are among the causes of many types of human cancer¹². Approximately 70% of *BRAF*-activating mutations occur in malignant melanomas, and the most common mutation is V600E, which changes valine to glutamic acid in codon 600 and accounts for approximately 95% of mutations in this gene¹³. This substitution has been observed with a lower frequency in other types of human cancer, including CRC at 10–20%¹⁴. As revealed in a recent meta-analysis, tumors with *BRAF* V600E mutations occur mainly on the right side of the colon, with a higher prevalence in women and elderly populations (over 60 years of age)¹⁵.

Notably, there is a mutually exclusive relationship between *KRAS* mutation and *BRAF* V600E¹⁶. Accordingly, the treatment strategies for patients can differ. In patients with *KRAS-wt*, the recommended first-line treatment is the administration of FOLFOX or FOLFIRI regimens, cetuximab or panitumumab, and

doublet chemotherapy. These may be considered for some patients with right-sided *RAS-wt* tumors to reduce cytotoxicity¹⁷.

In our study, the patient had *RAS-wt/BRAF* V600E mutation, which was observed with transverse colon involvement and liver metastasis. Thus, we started treatment with FOLFIRINOX (FFX) plus cetuximab. FOLFIRINOX has been recommended and extensively prescribed as a first-line treatment for patients with pancreatic ductal adenocarcinoma since 2011¹⁸. FFX includes leucovorin, FU, irinotecan, and oxaliplatin¹⁹, and this regimen plus cetuximab can be used in the first-line treatment of patients with metastatic CRC²⁰. After 12 cycles of this regimen, the liver metastatic lesions of our patient resolved, and colectomy was then performed. Because of the favorable response and poor prognosis of *BRAF* V600E mutations in the colon tumor, the patient received maintenance therapy, which included capecitabine (chemotherapy drug), vemurafenib (*BRAF* inhibitor), and cetuximab (*EGFR* inhibitor) and continued for more than 2 years; to date, the results have been promising.

Maintenance therapy generally consists of a less toxic portion of the previous regimen or an entirely disparate combination to which the patient has not formerly been exposed²⁰. This therapeutic strategy is performed in patients who have not responded to salvage therapy and is intended to extend the positive results achieved with first-line induction treatment²¹. Treatment continuation or medication break is left to the doctor's discretion. The advantages of drug vacations or therapeutic breaks include less toxicity, fewer hospital visits, better quality of life, and cost saving^{20,22}.

CONCLUSION

The use of FOLFIRINOX for complete response and resolution of metastatic lesions in patients with colon cancer with *RAS-wt/BRAF* V600E mutation is rarely reported. Our study showed that this combination plus a maintenance therapy strategy can lead to a complete and sustained therapeutic response. This strategy allows the selection of the most appropriate therapeutic method for the patient, yielding benefits such as cost savings and fewer hospital referrals. Our findings emphasize the importance of further investigations through larger prospective studies.

ABBREVIATIONS

BRAF: V-raf murine sarcoma viral oncogene homolog B1, **CBC:** complete blood count, **CRC:**

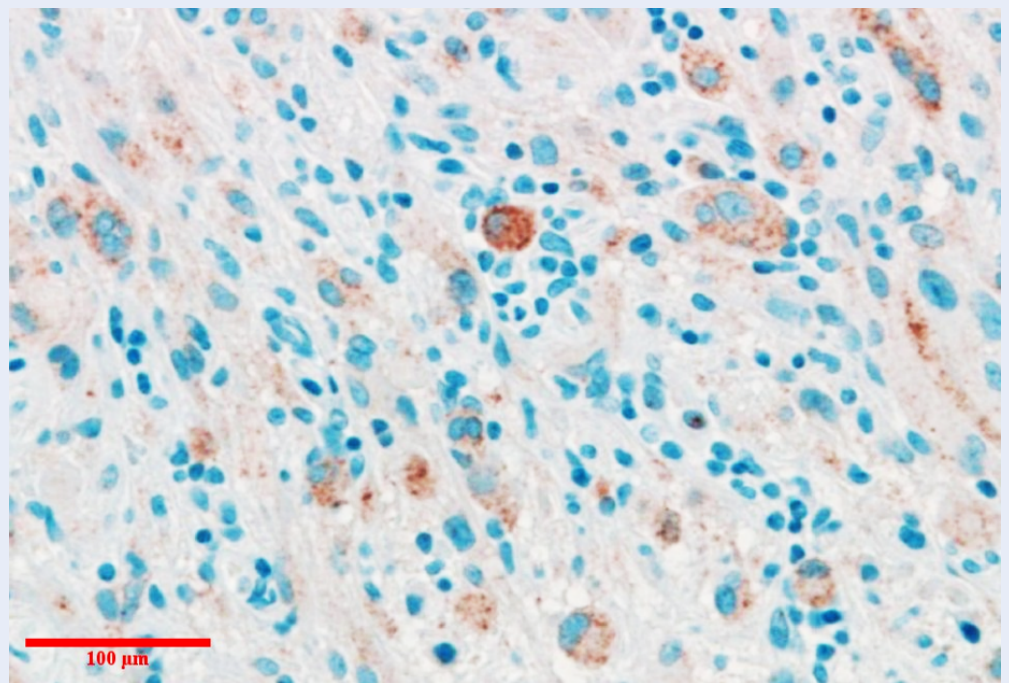


Figure 1: Immunohistochemistry showing the BRAF V600E mutated protein in the patient with metastatic colon cancer.

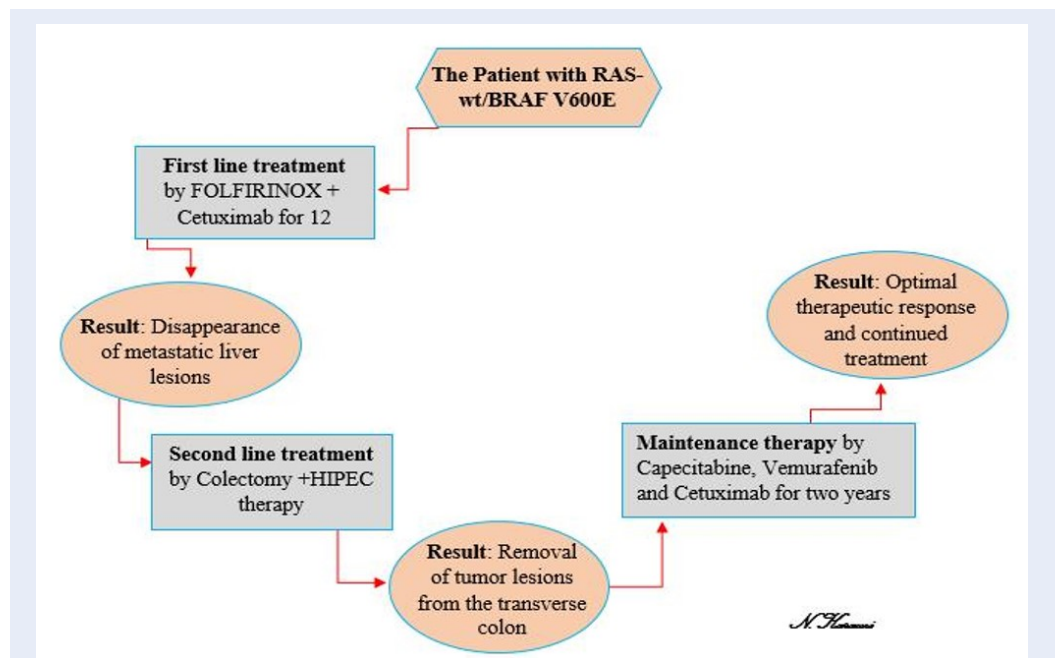


Figure 2: Diagram showing the maintenance therapy regimen in our study.

Colorectal Cancer, **EGFR**: Epidermal growth factor receptor, **FFX**: FOLFIRINOX, **Hb**: hemoglobin, **HIPEC**: Hyperthermic Intraperitoneal Chemotherapy, **IHC**: Immunohistochemistry, **MAPK**: mediated mitogen-activated protein kinase, **PI3K**: phosphatidylinositol 3-kinase, **WBC**: white blood cell.

ACKNOWLEDGMENTS

The authors are grateful to all colleagues in the Clinic of Hematology and Oncology.

AUTHOR'S CONTRIBUTIONS

Mehrdad Payandeh & Noorodin Karami: Literature search, Clinical studies, Data acquisition, Data analysis; Noorodin Karami: Manuscript preparation, Manuscript review, Guarantor; Afshin Karami: Concepts, Design, Definition of intellectual content, Literature search, Manuscript editing. All authors read and approved the final manuscript.

FUNDING

None.

AVAILABILITY OF DATA AND MATERIALS

None

ETHICS APPROVAL AND CONSENT TO PARTICIPATE

The procedures have been reviewed and approved by the ethics committee. All procedures were in accordance with the 1964 Declaration of Helsinki and its subsequent amendments or comparable ethical standards. Written informed consent was obtained from the patient to publish this case report and any accompanying images.

CONSENT FOR PUBLICATION

Not applicable.

COMPETING INTERESTS

The authors declare that they have no competing interests.

REFERENCES

- Bray F, Ferlay J, Soerjomataram I, Siegel RL, Torre LA, Jemal A. Global cancer statistics 2018: GLOBOCAN estimates of incidence and mortality worldwide for 36 cancers in 185 countries. *CA: a Cancer Journal for Clinicians*. 2018;68(6):394–424. PMID: 30207593. Available from: [10.3322/caac.21492](https://doi.org/10.3322/caac.21492).
- Deshwar A, Margonis GA, Andreatos N, Barbon C, Wang J, Buettner S. Double KRAS and BRAF mutations in surgically treated colorectal cancer liver metastases: an international, multi-institutional case series. *Anticancer Research*. 2018;38(5):2891–5. PMID: 29715113. Available from: [10.21873/anticancer.12535](https://doi.org/10.21873/anticancer.12535).
- Cirocchi R, Trastulli S, Abraha I, Vettoretto N, Boselli C, Montedori A. Non-resection versus resection for an asymptomatic primary tumour in patients with unresectable stage IV colorectal cancer; 2012. Available from: [10.1002/14651858.CD008997.pub2](https://doi.org/10.1002/14651858.CD008997.pub2).
- Maajani K, Khodadost M, Fattahi A, Shahrestanaki E, Pirouzi A, Khalili F. Survival rate of colorectal cancer in Iran: a systematic review and meta-analysis. *Asian Pacific Journal of Cancer Prevention*. 2019;20(1):13–21. PMID: 30677864. Available from: [10.31557/APJCP.2019.20.1.13](https://doi.org/10.31557/APJCP.2019.20.1.13).
- Ahmed M. Colon cancer: a clinician's perspective in 2019. *Gastroenterology Research*. 2020;13(1):1–10. PMID: 32095167. Available from: [10.14740/gr1239](https://doi.org/10.14740/gr1239).
- Hadjipetrou A, Anyfantakis D, Galanakis CG, Kastanakis M, Kastanakis S. Colorectal cancer, screening and primary care: A mini literature review. *World Journal of Gastroenterology*. 2017;23(33):6049–58. PMID: 28970720. Available from: [10.3748/wjg.v23.i33.6049](https://doi.org/10.3748/wjg.v23.i33.6049).
- Molina-Cerrillo J, Román MS, Pozas J, Alonso-Gordoa T, Pozas M, Conde E. BRAF mutated colorectal cancer: new treatment approaches. *Cancers (Basel)*. 2020;12(6):1571. PMID: 32545884. Available from: [10.3390/cancers12061571](https://doi.org/10.3390/cancers12061571).
- Taieb J, Lapeyre-Prost A, Puig PL, Zaanan A. Exploring the best treatment options for BRAF-mutant metastatic colon cancer. *British Journal of Cancer*. 2019;121(6):434–42. PMID: 31353365. Available from: [10.1038/s41416-019-0526-2](https://doi.org/10.1038/s41416-019-0526-2).
- Ducreux M, Chamseddine A, Laurent-Puig P, Smolenschi C, Hollebecque A, Dartigues P. Molecular targeted therapy of BRAF-mutant colorectal cancer. *Therapeutic Advances in Medical Oncology*. 2019;11:1758835919856494. PMID: 31244912. Available from: [10.1177/1758835919856494](https://doi.org/10.1177/1758835919856494).
- Wang Z, Dai WP, Zang YS. Complete response with fluorouracil and irinotecan with a BRAFV600E and EGFR inhibitor in BRAF-mutated metastatic colorectal cancer: a case report. *OncoTargets and Therapy*. 2019;12:443–7. PMID: 30662270. Available from: [10.2147/OTT.S180845](https://doi.org/10.2147/OTT.S180845).
- Mehta A, Gupta G, Nathany S. The mala fides of BRAF in oncogenesis. *Journal of Current Oncology*. 2019;2(2):37. Available from: [10.4103/jco.jco_25_19](https://doi.org/10.4103/jco.jco_25_19).
- Wan PT, Garnett MJ, Roe SM, Lee S, Niculescu-Duvaz D, Good VM, et al. Mechanism of activation of the RAF-ERK signaling pathway by oncogenic mutations of B-RAF. *Cell*. 2004;116(6):855–67. PMID: 15035987. Available from: [10.1016/s0092-8674\(04\)00215-6](https://doi.org/10.1016/s0092-8674(04)00215-6).
- Sahin IH, Kazmi SM, Yorjo JT, Bhadkamkar NA, Kee BK, Garrett CR. Rare though not mutually exclusive: a report of three cases of concomitant KRAS and BRAF mutation and a review of the literature. *Journal of Cancer*. 2013;4(4):320–2. PMID: 23569465. Available from: [10.7150/jca.3619](https://doi.org/10.7150/jca.3619).
- Taieb J, Zaanan A, Malicot KL, Julié C, Blons H, Mineur L. Prognostic effect of BRAF and KRAS mutations in patients with stage III colon cancer treated with leucovorin, fluorouracil, and oxaliplatin with or without cetuximab: a post hoc analysis of the PETACC-8 trial. *JAMA Oncology*. 2016;2(5):643–53. PMID: 26768652. Available from: [10.1001/jamaoncol.2015.5225](https://doi.org/10.1001/jamaoncol.2015.5225).
- Wang J, Shen J, Huang C, Cao M, Shen L. Clinicopathological significance of BRAFV600E mutation in colorectal cancer: an updated meta-analysis. *Journal of Cancer*. 2019;10(10):2332–41. PMID: 31258736. Available from: [10.7150/jca.30789](https://doi.org/10.7150/jca.30789).
- Caputo F, Santini C, Bardasi C, Cerma K, Casadei-Gardini A, Spallanzani A. BRAF-mutated colorectal cancer: clinical and molecular insights. *International Journal of Molecular Sciences*. 2019;20(21):5369. PMID: 31661924. Available from: [10.3390/ijms20215369](https://doi.org/10.3390/ijms20215369).
- Folprecht G, Martinelli E, Mazard T, Modest DP, Tsuji A, Esser R. Triplet chemotherapy in combination with anti-EGFR agents for the treatment of metastatic colorectal cancer: current evidence, advances, and future perspectives. *Cancer Treatment Reviews*. 2022;102:102301. PMID: 34839118. Available from: [10.1016/j.ctrv.2021.102301](https://doi.org/10.1016/j.ctrv.2021.102301).

18. Franck C, Canbay A, Malfertheiner P, Venerito M. Maintenance therapy with FOLFIRI after FOLFIRINOX for advanced pancreatic ductal adenocarcinoma: a retrospective single-center analysis. *Journal of Oncology*. 2019;2019:5832309. PMID: 31885579. Available from: [10.1155/2019/5832309](https://doi.org/10.1155/2019/5832309).
19. Hatachi Y, Mohan SR, Kotake T, Satake H, Okita Y, Yasui H, et al. FOLFIRINOX as First-line Chemotherapy in Japanese Patients Suffering from Metastatic Pancreatic Cancer (Kobe FOLFIRINOX Study). *Cancer Diagnosis & Prognosis*. 2022;2(1):101–6. PMID: 35400007. Available from: [10.21873/cdp.10083](https://doi.org/10.21873/cdp.10083).
20. Aprile G, Giuliani F, Lutrino SE, Fontanella C, Bonotto M, Rihawi K. Maintenance therapy in colorectal cancer: moving the Artillery down while keeping an eye on the enemy. *Clinical Colorectal Cancer*. 2016;15(1):7–15. PMID: 26421728. Available from: [10.1016/j.clcc.2015.08.002](https://doi.org/10.1016/j.clcc.2015.08.002).
21. Cutsem EV, Cervantes A, Nordlinger B, Arnold D, Group EGW. Metastatic colorectal cancer: ESMO Clinical Practice Guidelines for diagnosis, treatment and follow-up. *Annals of Oncology : Official Journal of the European Society for Medical Oncology*. 2014;25:iii1–9. PMID: 25190710. Available from: [10.1093/annonc/mdu260](https://doi.org/10.1093/annonc/mdu260).
22. Sonbol MB, Mountjoy LJ, Firwana B, Liu AJ, Almader-Douglas D, Mody K, et al. The role of maintenance strategies in metastatic colorectal cancer: A systematic review and network meta-analysis of randomized clinical trials. *JAMA oncology*. 2020;6(3):e194489. PMID: 31855256. Available from: [10.1001/jamaoncol.2019.4489](https://doi.org/10.1001/jamaoncol.2019.4489).